

Healing Incisional Surgical Wounds Using Rose Hip Oil in Rats*

ORIGINAL

Lainy Carollyne da Costa Cavalcante¹, Thyago Cezar Prado Pessôa¹,
Rubens Fernando Gonçalves Ribeiro Júnior², Edson Yuzur Yasojima³,
Rosa Helena de Figueiredo Chaves Soares⁴, Marcus Vinicius Henriques Brito⁵,
Eduardo Henrique Herbster Gouveia¹, Lucas Nascimento Galvão¹, Suzana Rodrigues Ramos¹,
Adan Kristian Almeida Carneiro¹, Yuri Aarão Amaral Serruya¹, Mateus Malta de Moraes¹

Abstract

Purpose: To evaluate incisional surgical wound healing in rats using Rose Hip (*Rosa rubiginosa* L.) oil.

Methods: Twenty-one days after oophorectomy procedure, twenty-seven female, adult, Wistar rats were distributed into three groups: Control group (wound treatment with distilled water); Collagenase group (treatment with collagenase ointment); and Rose Hip group (wound treatment with Rose Hip oil). Each group was distributed according to date of euthanasia: 7th, 14th and 21st postoperative day. The wound was evaluated considering macroscopic and microscopic parameters.

Results: The results indicated differences in healing of incisional wounds between collagenase and Rose Hip treatments when compared to control group. Accelerated wound healing was observed in Rose Hip oil compared to control and collagenase group, especially after the 14th day. Morphometric data confirmed structural findings.

Conclusion: There was significant effect in topical application of Rose Hip oil on improvement of incisional surgical wound healing when compared to collagenase and control group.

1 Graduate Medical Student, CESUPA, Belém-PA, Brazil.

2 Master in Surgery and Experimental Research (CIPE), Laboratory of Experimental Surgery (LCE), State University of Pará (UEPA), Brazil.

3 PhD, Full Professor, Medical School, CESUPA, Brazil.

4 Fellow PhD Degree, Postgraduate Program in Animal Health and Production in Amazon, Federal Rural University of Amazonia, Pará, Brazil

5 PhD, Full Professor, Medical School, State University of Pará (UEPA), Brazil.

*: Research performed at Experimental Research Group (GPE). University Center of Pará State (CESUPA), Belém, PA, Brazil.

Contact information:

Rubens Fernando Gonçalves Ribeiro Júnior.

Address: Marquês de Herval Av. 1823. Pedreira. 66087-320. Belém-PA, Brazil.

✉ rubensfernandojr@gmail.com

Keywords

Medicinal Plants; Collagen; Wound Healing; Rats.

Introduction

The healing process is common to all wounds, regardless of the agent that caused it, is systemic and dynamic and relates directly to the general conditions of the body [1, 2]. The topical use of substances for improving the healing process has been widely studied [3].

Brazil has the largest diversified forest reserve on the planet. Many of these species used for medicinal purposes are consumed with little or no evidence of their pharmacological properties. The use of medicinal plants is not restricted to rural areas or regions devoid of medical and pharmaceutical care. They are also used extensively in urban areas, as an alternative or complement to allopathic medicines [4].

The Rose Hip (*Rosa rubiginosa L.*) belongs to the genus *Rosa*, Rosaceae family, and has approximately 70 different species worldwide [5]. Native to the Mediterranean region and Central Europe, was brought to South America by Spanish colonizers, and grows in south and central Chile [6] as a wild plant, beneath dry soils agricultural value [7].

The objective of this study was to investigate the effects of Rose Hip (*Rosa rubiginosa L.*) oil on the healing of incisional surgical wounds in rats.

Methods

Twenty-seven (15-20 weeks) female Wistar rats (*Rattus norvegicus*) weighting 250-350g were used in this study. The animals were kept in a vivarium of the Experimental Research Group at the Centro Universitário do Estado do Pará (GPE-CESUPA) with a controlled temperature, light, humidity, and noise; water and food was provided *ad libitum*. The project was previously approved by the Animal Use and Care Committee of University Center of the Pará State (Protocol 02/2014) and followed the rules of Brazilian National Law for Animal Care (Law: 11.794/08).

Experimental protocol

Three groups of study comprised this study:

- Control Group (CG): distilled water were applied everyday and once in a day until euthanasia, a volume of 0.3 ml.
- Collagenase Group (CLG): collagenase ointment (0.6 U/g) were applied everyday and once in a day, a volume of 0.3 ml until euthanasia.
- Rose Hip Group (RG): Rose Hip oil were applied everyday and once in a day until euthanasia, a volume of 0.3 ml.

Animals were then randomly assigned into three subgroups (N= 3 each): Distilled Water Group seven, 14 and 21 days (CG7, CG14 and CG21), Collagenase Group seven, 14 and 21 days (CLG7, CLG14 and CLG21) and Rose Hip Group seven, 14 and 21 days (RG7, RG14 and RG21) according to the time elapsed from surgery to animal euthanasia.

Oophorectomy

All animals were anesthetized with ketamine hydrochloride (70 mg/kg) and xylazine hydrochloride (10 mg/kg), submitted to trichotomy and then a 2cm laparotomy was performed to reach the ovaries, which were switched both proximal and distal at 1cm distance from the cervix and then sectioned. The laparorrhaphy was performed with 4-0 nylon. After 21 days, the female rats were subjected to exfoliative vaginal cytology, then, the content was deposited on the surface of a glass dish, which was immersed into absolute alcohol for fixation. The glass dishes were stained by Shorr (1941) [8] method and then analyzed using an optical microscope in order to characterize the estral cycle, to confirm anoestrus [9].

Surgical procedures

21 days after oophorectomy, all surgical procedures were performed newly under anesthesia. Dorsal region was shaved and then antiseptics of region was done. Next, a full-thickness skin surgical incision measuring 20 mm in length and 2 mm in depth was

made in the skin of the back of the animal in the caudocranial direction and incision was not sutured [10]. During postoperative days, animals remained in individual cages and isolated from their bedding through a metallic net to avoid wound infection. The rats were euthanized by anesthetic overdose.

Macroscopic analysis

To determine the largest diameter of the wound and its macroscopic used a magnifying glass with 2.5x. The wound was measured with a pachymeter graduated in millimeters to calculate the area.

Histological analysis

After euthanasia, wounds were harvested, fixed in 10% formaldehyde, embedded in paraffin, stained using Hematoxyline-Eosine (HE). In HE stained tissues, multiple sections were analyzed with regard to the presence of re-epithelialization, intensity of local inflammatory reaction, type of inflammatory response as the predominant cell, the presence of granulation tissue, neovascularization and fibrosis [11].

Statistics

Analysis of variance (ANOVA), followed by Tukey *posthoc* test correction, was performed for the macroscopic analysis and proportion of collagen fibers. Kruskal-Wallis test was used for the histological parameters. Statistical significance was assumed at $p < 0.05$.

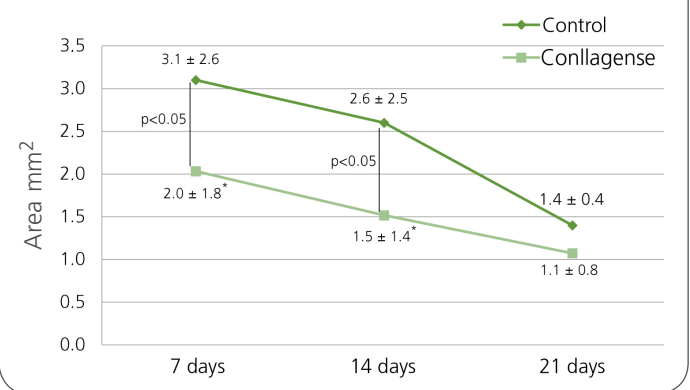
Results

No significant differences in age and body weight of the animals were found between the study before and after the intervention.

Macroscopic results

Comparing the groups according to the time of measurement, a statistical difference was observed between Control and Collagenase (Figure 1), in 7th ($p=0.0373$) and 14th day ($p=0.0367$). It was

Figure 1: Wound area within days. * $p < 0.05$ versus Control group. ANOVA (Tukey) test.



also found a difference between Control and Rose Hip oil (Figure 2) in 14th ($p=0.0275$) and 21st day ($p=0.0008$). In addition, when comparing collagenase and Rose Hip oil (Figure 3), there was difference only in 21st day ($p=0.0364$).

Figure 2: Wound area within days. * $p < 0.05$ versus Control group. ANOVA (Tukey) test.

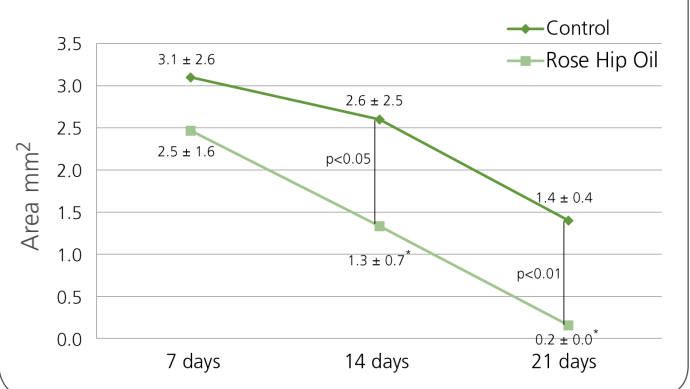
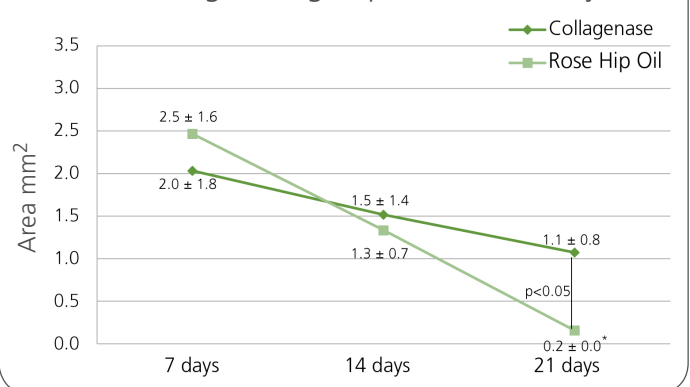


Figure 3: Wound area within days. * $p < 0.05$ versus Collagenase group. ANOVA (Tukey) test.



Microscopic results

There was no statistical difference between the groups at different times regarding the degree of re-epithelialization and the presence of granulation tissue. However, predominance of chronic response type was noted in the groups at all wound evaluation times and was observed statistically difference regarding the intensity of the local inflammatory response with predominance of monomorphonuclear infiltrate at different times of collagenase and Rose Hip oil groups, when compared to the control group ($p=0.0498$ and $p=0.0442$, respectively).

Discussion

Several substances have been tested in wound healing process. However, the results are not always satisfactory when compared to the control group or even active compounds may slow the overall wound healing. Therefore, the study of incisional wound healing becomes of great value for scientific knowledge.

Throughout the experimental part of this article, all animals evolved well postoperatively, be it 7, 14 or 21 days without causing infection, death or replacement of animals to the study, proving that this model of incisional wound induction was efficient.

Proteolytic enzymes have been used in wound healing for many years and the most commonly used enzymes are fibrinolysin/DNAse and collagenase [12,13,14], where collagenases act by degrading native helical collagen fibrils [15]. Recently, Tallis et al. (2013) showed that the collagenase ointment is tolerable and clinically effective in providing non-viable tissue removal and allow effective scar [16].

There was a significant difference in collagenase with control group on days 7 and 14, which demonstrates its mechanism of action, especially in the acute phase of incisional wound healing, not observed statistical difference on day 21 due to the

lower effectiveness of its action against the chronicity of the incisional wound.

However, Rose Hip oil showed surprising results compared to the control group, obtaining a lower average of the wound area when compared to the other groups. Mainly in the macroscopy where a degree of almost total contraction of the incisional wound was observed on 21 day.

The uses of Rose Hip scientifically reported so far are as functional food, antioxidant, osteoarthritis care, antiinflammatory, antidiabetic, cardioprotective, antimicrobial, immunomodulatory, gastroprotective and dermatological applications [17–21].

In a clinical study with a control group, the authors demonstrated an improvement in the time and quality of healing among patients using Rosa Mosqueta oil in comparison to the control group. Evaluated patients with varicose ulcers, post-traumatic ulcers and contact eczema. All showed positive results in relation to the comparison group, occurring a difference of up to 29 days of healing among the groups [22].

As noted, Rose Hip oil has proved to be a better treatment in the retraction of the wounds, especially for a late mechanism of action. Having more effective from the 14th day of incisional wound, compared to the control and collagenase group, maintaining a lower chronic inflammatory response, characterized by monomorphonuclear infiltration.

Previous studies have found active compounds of Rose Hip oil, concentrations of fatty acids [23] in the following order: unsaturated fatty acids: linoleic acid (between 43 and 49%), linolenic acid (between 32 and 38%), oleic acid (Between 14 and 16%); Saturated fatty acids: palmitic acid (between 3 and 5%), palmitoleic acid (between 0.1 and 5%), stearic acid (between 1 and 2%), other fatty acids such as lauric, myristic, arachidonic, gadolinic and behenic from 0 to 1%); Active acids: transretinoic acid or natural tretinoin (0.01 to 0.1%).

Essential fatty acids are required for many physiological processes, such as maintaining the integrity

of the skin and the structure of cell membranes and the synthesis of biologically active compounds. Among the health benefits attributed to fatty acids are: anticarcinogenesis, antiatherosclerosis, inhibition of free radicals, alteration in the composition and metabolism of adipose tissue, immunomodulation, antibacterial and antidiabetic activity [24].

The essential fatty acids also have a structural function, forming part of the phospholipids of the cellular membranes of the tissues of the organism, being the precursors of prostaglandins and leukotrienes from the synthesis of arachidonic acid [24, 25]. Already phospholipids involved in various metabolic processes, such as the active phosphorylation process in mitosis and cell organization and ion exchange, which gives the Rose Hip oil a high potential in the treatment of wound healing [26].

We must consider that human skin differs from rat and the important difference is that human skin cures preferentially by re-epithelialization, whereas the skin of the rat heal mainly by contraction of the wound [27]. We also recognize the limitations for translational relevance of our experimental study. However, skin lesions in animal models are relevant because they provide significant contributions to advances in the treatment of incisional wounds.

The experimental model demonstrated greater efficacy of topical application of Rose Hip oil in tissue formation, epithelialization, angiogenesis and collagen deposition in skin lesion compared to the other groups.

Conclusion

Rose Hip oil is able to reduce intensity of inflammatory response of the wound, maintaining the same type of inflammatory response when compared to the collagenase group, proven by macroscopic results, in which there was a greater retraction of wound in animals treated with oil and no evidence of incisional wound healing impaired.

Conflict of Interest

None

Financial Sources

PIBICT-CESUPA.

References

1. George Broughton II, Janis JE, Attinger CE. Wound healing: an overview. *Plastic and reconstructive surgery*. 2006 117(7S): 1e-S. doi: 10.1097/01.prs.0000222562.60260.f9.
2. Attinger CE, Janis JE., Steinberg J, Schwartz J, Al-Attar A, Couch K. Clinical approach to wounds: debridement and wound bed preparation including the use of dressings and wound-healing adjuvants. *Plast Reconstr Surg*. 2006 Jun; 117(7 Suppl):725-109S. doi: 10.1097/01.prs.0000225470.42514.8f.
3. Manoel FSS, Czezko NG, Nassif PAN, Ribas-Filho JM, Alencar BLF, Malafaia O, et al. Evaluation of the use of raw extract of *Jatropha gossypifolia L.* in the healing process of skin wounds in rats. *Acta Cir. Bras*. 2006 21(Suppl 3): 2-7. doi: 10.1590/S0102-86502006000900002.
4. Santos OJ, Torres OJM. Phytotherapy evolution in the healing process in surgery. *Arq Bras Cir Dig*. 2012 Jul-Sep; 25(3):139. doi: 10.1590/S0102-67202012000300001.
5. Dogan A, Kazankaya A. Fruit properties of Rose hip species grown in lake Van Basin (eastern Anatolia region). *Asian J. Plant Sci*. 2006 5(1):120-2. doi: 10.3923/ajps.2006.120.122.
6. Eggers R, Ambrogi A, Schnitzler J Von. Special features of SCF solid extraction of natural products: deoiling of wheat gluten and extraction of rose hip oil. *Braz. J. Chem. Eng*. 2000 Sep; 17(3):329-334. doi: 10.1590/S0104-66322000000300009.
7. Robert P, Carlsson R, Romero N, Masson L. Stability of spray-dried encapsulated carotenoid pigments from *Rosa mosqueta (Rosa rubiginosa)* oleoresin. *J Amer Oil Chem Soc*. 2003 Nov; 11(80), 1115-1120. doi: 10.1007/s11746-003-0828-4.
8. Shorr E. A new technique for staining vaginal smears: III, a single differential stain. *Science*. 1941 Dec; 94(2449):545-6. doi: 10.1126/science.95.2469.438.
9. Brito NMB, Carvalho RKV, Matos LTMB, Lobato RC, Brito RB. The oophorectomy effect on Walker 256 tumor inoculated into the vagina and uterine cervix of female rats. *Acta Cir Bras*. 2009 Jan-Feb; 24(1):26-9. doi: 10.1590/S0102-86502009000100006.
10. Passarini Junior JR, Esquisatto MA, Mendonça JS, Franchini CC, Santos GM. Effects of the application of Aloe vera (L.) and microcurrent on the healing of wounds surgically induced in Wistar rats. *Acta Cir Bras*. 2009 Mar-Apr; 24(2):150-5. doi: 10.1590/S0102-86502009000200013.

11. Santos LOM, Simões MLPB, Machado APB, Matioski FGR, Endo PC, Gruen GR, et al. Effect of somatotropin on skin wound healing in rats. *Acta Cir. Bras.* 2002 Jul-Aug; 17(4):220-224. doi: 10.1590/S0102-86502002000400004.
12. Peter FW, Li-Peuser H, Vogt PM, Muehlberger T, Homann HH, Steinau HU. The effect of wound ointments on tissue microcirculation and leucocyte behaviour. *Clin Exp Dermatol.* 2002 Jan; 27(1):51-5. doi: 10.1046/j.0307-6938.2001.00937.x.
13. Marazzi M, Stefani A, Chiaratti A, Ordanini MN, Falcone L, Rapisarda V. Effect of enzymatic debridement with collagenase on acute and chronic hard-to-heal wounds. *J Wound Care.* 2006 May; 15(5):222-7. doi: 10.12968/jowc.2006.15.5.26910.
14. Ostlie DJ, Juang D, Aquayo P, Pettiford-Cunningham JP, Erkmann EA, Rash DE, et al. Topical silver sulfadiazine vs collagenase ointment for the treatment of partial thickness burns in children: a prospective randomized trial. *J Pediatr Surg.* 2012 Jun; 47(6):1204-7. doi: 10.1016/j.jpedsurg.2012.03.028.
15. Mekkes JR, Zeegelaar JE, Westerhof W. Quantitative and objective evaluation of wound debriding properties of collagenase and fibrinolysin/desoxyribonuclease in a necrotic ulcer animal model. *Arch Dermatol Res.* 1998 Mar; 290(3):152-7. doi: 10.1007/s004030050281.
16. Tallis A, Motley TA, Wunderlich RP, Dickerson Jr JE, Waycaster C, Slade HB, et al. Clinical and economic assessment of diabetic foot ulcer debridement with collagenase: results of a randomized controlled study. *Clin Ther.* 2013 Nov; 35(11):1805-20. doi: 10.1016/j.clinthera.2013.09.013.
17. Yilmaz SO, Ercisli S. Antibacterial and antioxidant activity of fruits of some rose species from Turkey. *Rom Biotech Lett.* 2011 16(4), 6407-6411.
18. Guo D, Xu L, Cao X, Guo Y, Ye Y, Chan C-O, Mok DKW, Yu Z, Chen S. Anti-inflammatory activities and mechanisms of action of the petroleum ether fraction of *Rosa multiflora* Thunb. hips. *J Ethnopharmacol.* Dec 2011 8; 138(3):717-22. doi: 10.1016/j.jep.2011.10.010.
19. Mabellini A, Ohaco E, Ochoa MR, Kessler AG, Márquez CA, De Michelis A. Chemical and physical characteristics of several wild rose species used as food or food ingredient. *Int J Ind Chem.* 2011 2:158-171.
20. Yi O, Jovel EM, Towers GH, Wahbe TR, Cho D. Antioxidant and antimicrobial activities of native *Rosa* sp. From British Columbia, Canada. *Int J Food Sci Nutr.* 2007 May; 58(3):178-89. doi: 10.1080/09637480601121318.
21. Rosu CM, Manzu C, Olteanu Z, Oprica L, Oprea A, Ciornea E, Zamfirache MM. Several fruit characteristics of *Rosa* sp. genotypes from the North-eastern region of Romania. *Not Bot Horti Agrobo.* 2011 39:203-208. doi: 10.15835/nbha3926333.
22. Santos JS, Vieira AB, Kamada I. Treatment of open wounds using Mosqueta Rose: a review. *Rev Bras Enferm.* 2009 May-Jun; 62(3):457-62. doi: 10.1590/S0034-71672009000300020.
23. Valladares J, Palma M, Sandoval C, Carvajal F. Crema de aceite de mosqueta (*rosa* aff. *Rubiginosa* L.). I. Parte: formulación, preparación y aplicación primaria en regeneración de tejidos. *Anales Real Acad Farm.* 1986; 52(3): 597-612.
24. Funck LG, Barrera-Arellano D, Block JM. Conjugated Linoleic Acid (CLA) And Its Relationship With Cardiovascular Disease And Associated Risk Factors. *Arch Latinoam Nutr.* 2006; 56(2).
25. Pareja B. Dermopharmacy: medicinal plants with applications in dermatology and cosmetics. *Folia Dermat Peruana.* 1996 7(3/4):48-52.
26. Godoy JMP, Prado PA. Ácidos gordos essenciais enriquecidos com vitamina A, E e ácido linoleico como pensos em feridas crônicas. *Rev Port Clin Geral.* 2005 21:193-5.
27. Szentmihályi K, Vinkler P, Lakatos B, Illés V, Then M. Rose hip (*Rosa canina* L.) oil obtained from waste hip seeds by different extraction methods. *Bioresour Technol.* 2002 82(2): 195-201. doi: 10.1016/S0960-8524(01)00161-4.

Publish in International Archives of Medicine

International Archives of Medicine is an open access journal publishing articles encompassing all aspects of medical science and clinical practice. IAM is considered a megajournal with independent sections on all areas of medicine. IAM is a really international journal with authors and board members from all around the world. The journal is widely indexed and classified Q2 in category Medicine.